

**UNIVERSIDAD SAN FRANCISCO DE QUITO USFQ**

**Colegio de Posgrados**

**Thoracic tomographic findings in pediatric patients with COVID-19 and asthma: a systemic review.**

**Martínez Maldonado Diego Alejandro**

**Jonathan Raymond Guillemot**  
**Director del Instituto de Medicina Social & Desafíos Globales**  
**Profesor**  
**Director de Trabajo de Titulación**

Trabajo de fin de carrera presentado como requisito  
para la obtención del título de Especialista en Imagenología

Quito, 10 de junio de 2022

# UNIVERSIDAD SAN FRANCISCO DE QUITO USFQ

## Colegio de Posgrados

### HOJA DE CALIFICACIÓN DE TRABAJO DE FIN DE CARRERA

**Thoracic tomographic findings in pediatric patients with COVID-19 and asthma: a systemic review.**

Martínez Maldonado Diego Alejandro

Nombre del Director del Programa: Verónica Espinoza Arregui  
Título académico: Especialización en Imagenología  
Director del programa de: Especialización en Imagenología

Nombre del Decano del colegio Académico: Gonzalo Mantilla  
Título académico: Decano de COCSA  
Decano del Colegio: Colegio Ciencias de la Salud

Nombre del Decano del Colegio de Posgrados: Hugo Burgos Yánez  
Título académico: Decano Colegio de Posgrados

Quito, 10 de junio de 2022

## © DERECHOS DE AUTOR

Por medio del presente documento certifico que he leído todas las Políticas y Manuales de la Universidad San Francisco de Quito USFQ, incluyendo la Política de Propiedad Intelectual USFQ, y estoy de acuerdo con su contenido, por lo que los derechos de propiedad intelectual del presente trabajo quedan sujetos a lo dispuesto en esas Políticas.

Asimismo, autorizo a la USFQ para que realice la digitalización y publicación de este trabajo en el repositorio virtual, de conformidad a lo dispuesto en la Ley Orgánica de Educación Superior del Ecuador.

Nombres y apellidos:                   Martínez Maldonado Diego Alejandro

Código:                                    213373

Cédula de identidad:                 1724524556

Lugar y fecha:                          Quito, 10 de junio de 2022

## **ACLARACIÓN PARA PUBLICACIÓN**

**Nota:** El presente trabajo, en su totalidad o cualquiera de sus partes, no debe ser considerado como una publicación, incluso a pesar de estar disponible sin restricciones a través de un repositorio institucional. Esta declaración se alinea con las prácticas y recomendaciones presentadas por el Committee on Publication Ethics COPE descritas por Barbour et al. (2017) Discussion document on best practice for issues around theses publishing, disponible en <http://bit.ly/COPETheses>.

## **UNPUBLISHED DOCUMENT**

**Note:** The following capstone project is available through Universidad San Francisco de Quito USFQ institutional repository. Nonetheless, this project – in whole or in part – should not be considered a publication. This statement follows the recommendations presented by the Committee on Publication Ethics COPE described by Barbour et al. (2017) Discussion document on best practice for issues around theses publishing available on <http://bit.ly/COPETheses>.

## **DEDICATORIA**

Dedico este trabajo a mis padres Jimena y Arturo, a mi hermano Arturo y a mi esposa Andrea por ser mi fortaleza, mi guía y mi apoyo, por estar siempre presentes en este arduo camino y acompañarme a alcanzar mis metas.

## **AGRADECIMIENTOS**

Agradezco a Dios y a mi familia porque han sido el eje para que este objetivo se cumpla.

A mis profesores por toda su entrega, paciencia y por enseñarme a apasionarme de esta hermosa aventura que es la radiología.

A mi director de este trabajo, Jonathan Guillemot por su tiempo, paciencia, apoyo y dedicación.

## RESUMEN

**ANTECEDENTES:** COVID-19 es una infección causada por un nuevo coronavirus, que causa una enfermedad respiratoria grave y ha sido declarado pandemia por la Organización Mundial de la Salud. Los niños se ven menos afectados que los adultos, aunque los resultados de la tomografía computarizada de tórax no se han informado ampliamente. Las comorbilidades como el asma que sugieren COVID-19 en poblaciones pediátricas podrían conducir a peores resultados. **OBJETIVO:** Revisar sistemáticamente la literatura disponible sobre los hallazgos tomográficos de tórax en casos pediátricos con asma afectados por COVID-19. **MATERIALES Y MÉTODOS:** Se buscaron artículos en dos bases de datos (Pubmed y Scopus) que describieran hallazgos tomográficos en niños asmáticos afectados por COVID-19. Se incluyeron estudios que investigaron pacientes menores de 18 años, con antecedentes de asma, que desarrollaron COVID-19 y a quienes se les realizó un estudio tomográfico como parte de su manejo hospitalario. **RESULTADOS:** Se incluyeron once artículos. En el momento del diagnóstico, la mayoría de los niños tenían una tomografía computarizada normal, incluidos los niños asmáticos. En la tomografía anormal, el patrón tomográfico más común fue opacificación en vidrio esmerilado y opacidades en parche. La mayoría de estas tomografías tenían una distribución difusa y afectación de ambos campos pulmonares. Los niños con COVID-19 a menudo son asintomáticos o tienen una enfermedad leve. Algunos de ellos tienen comorbilidades crónicas como asma o enfermedades alérgicas; estos niños infectados por COVID-19 se presentaron en menor número en relación al resto de la población pediátrica. En este sentido, el asma no aumenta la susceptibilidad, la morbilidad y no es un factor predisponente para la infección por COVID-19. **CONCLUSIÓN:** Los resultados de la tomografía computarizada de tórax en niños con y sin asma afectados por COVID-19 suelen ser normales o leves. La tomografía computarizada de tórax brinda información

importante para el manejo del paciente y debe reservarse para casos graves, falla del tratamiento o aquellos en estado crítico.

**Palabras clave:** niños, COVID-19, asma, tomografía computarizada



## ABSTRACT

**BACKGROUND:** COVID-19 is an infection caused by a new coronavirus, which causes severe respiratory illness and has been declared a pandemic by the World Health Organization. Children are less affected than adults, although chest computed tomography results have not been widely reported. Comorbidities such as asthma that suggest COVID-19 in pediatric populations could lead to poorer outcomes. **OBJECTIVE:** To systematically review the available literature on chest tomographic findings in pediatric cases with asthma affected by COVID-19. **MATERIALS AND METHODS:** Two databases (Pubmed and Scopus) were searched for articles describing tomographic findings in asthmatic children affected by COVID-19. We included studies investigating patients aged <18 years, with a history of asthma, developed COVID-19 and who underwent a tomographic study as part of their hospital management. **RESULTS:** Eleven articles were included. At the time of diagnosis, the majority children had a normal computed tomographic, included the asthmatic children. In the tomographic abnormal, the most common tomographic pattern was ground glass opacification and patch opacities. Most of these tomographies had a diffuse distribution and involvement of both lung fields. Children with COVID-19 are often asymptomatic or have mild illness. Some of them have chronic comorbidities such as asthma or allergic diseases; these children infected by COVID-19 presented in smaller numbers in relation to the rest of the pediatric population. In this sense, asthma does not increase susceptibility, morbidity and is not a predisposing factor for COVID-19 infection. **CONCLUSION:** Computed tomographic results of the chest in children with and without asthma affected by COVID-19 are usually normal or mild. Chest computed tomography provides important information for patient management and should be reserved for severe cases, treatment failure, or those in critical condition.

**Keywords:** child; COVID-19; Asthma; Multidetector Computed Tomography.

**TABLE OF CONTENTS**

Resumen .....	7
Abstract .....	9
Introduction .....	14
Methods .....	16
Results .....	20
Discussion and conclusion.....	26
References .....	27

**TABLE INDEX**

Table 1. PICOS .....	16
Table 2. PUBMED research strategy Abstract .....	17
Table 3. Scopus research strategy Introduction .....	18
Table 4. Eligibility criteria .....	19
Table 5. Citations list .....	20
Table 6. Tomographic thorax patterns of COVID-19 in children with and without asthma .....	23
Table 7. Distribution of pediatric population with and without asthma and affected by COVID-19 .....	25
Table 8. Laterality of COVID-19 thorax tomographic findings in children with and without asthma .....	24
Table 9. Distribution of abnormal tomographic findings in the lung fields .....	24

**FIGURE INDEX**

Figure 1. PRISMA .....	21
------------------------	----

## INTRODUCTION

In December 2019, in Wuhan, China, a novel coronavirus that caused Severe Acute Respiratory Syndrome Coronavirus 2 or SARS-CoV-2 and the associated disease, COVID-19 [1,2], was later declared as a pandemic by the World Health Organization (WHO) on March 2020 [3]. COVID-19 is a respiratory infection transmitted directly between people through sputum or saliva droplets [4]. This infection causes primarily lung lesions due to the propagation of the virus from the upper to the lower respiratory tract [4].

The understanding of COVID-19 is constantly being updated, which is why some comorbidities including asthma were believed to cause worse outcomes; but it is currently known that the severity and complications of COVID-19 infection are related to hyperinflammation and this is decreased in asthmatic patients. This decrease is associated with several factors including: a) diminished expression of the angiotensin-2 converting enzyme (ACE2) receptors in the respiratory epithelium, which is the same cellular receptor as SARS-CoV-2; b) reduces production of IFN- $\alpha$  caused by dendritic and bronchial epithelial cells; and c) reduced viral load and SARS-CoV-2 infection caused by the generation of type 2 eosinophilic inflammation [5,6,7]. It was initially thought that children were not susceptible to COVID-19; however, as the disease has progressed, the number of pediatric patients has grown exponentially [4,8,9]. Most pediatric COVID-19 patients present mild to moderate symptoms, and very few cases have been described as serious or critical [10,11,12].

Thoracic imaging (X-ray and tomography) plays an important role in COVID-19 patient management. It provides information not only for the initial diagnosis but also for disease follow-up and for the assessment of treatment [12]. However, the use of tomography in children is controversial due to the high radiation load [13]. There are several systematic

reviews on COVID-19 tomographic findings of adult population, and there is limited information on pediatric information [12,14]. However, none of them focus on pediatric population with asthma. Therefore, this systematic review offers an overview of tomographic characteristics of pediatric population with asthma to further describe thoracic tomographic findings in asthmatic pediatric patients infected with SARS-CoV-2?

## METHODS

Preferred Reporting Items for Systematic reviews and Meta-Analyses (PRISMA) guidelines and the PICOS (Population, Intervention, Comparator, Outcomes and Study type) framework were taken into consideration to formulate the research question (Table 1). Pubmed (Table 2) and Scopus (Table 3) databases were employed for bibliographic search of published articles that described the tomographic findings of the chest in the asthmatic pediatric population with COVID-19. For the selection of the articles, the following research terms were employed: child; COVID-19; Asthma; Multidetector Computed Tomography.

**Table 1. PICOS**

ITEM	DEFINITION
Population	Children with asthma and COVID-19
Interventions	No applicable
Comparators	No applicable
Outcomes	Tomographic findings
Study Type	Observational studies, prospective and retrospective studies with eligible baseline outcomes.

All articles, including case reports, which focused on thoracic infection due to COVID-19 in patients ages 0 to 18 were examined and included in this review. There were no restrictions regarding the number of cases or type of clinical environment. Exclusion criteria included duplicates or consisted of unconfirmed cases of COVID-19 (suspected cases), systematic reviews, meta-analysis, editorial, clinical guidelines, studies which had no results on thoracic imaging, no asthmatic patients or a mixed cohort between adults and children (Table 4).



Table 2. PUBMED research strategy

SEARCH DATE: 22/02/2022		PUBMED	
Items	#	Search terms	Number of citations
Population_children	#1	Child[MeSH] OR infant[MeSH] OR pediatrics[MeSH] OR adolescent[MeSH]	3.827.795
	#2	infan*[TIAB] OR child*[TIAB] OR pediatri*[TIAB] OR paediatric*[TIAB] OR adolescen* [TIAB] OR preschool [TIAB]	2.226.001
	#3	#1 OR #2	4.369.754
Population_SARS-CoV2	#4	COVID-19[MeSH] OR SARS-CoV-2[MeSH] OR coronavirus [MeSH]	155.071
	#5	"COVID-19"[TIAB] OR COVID19[TIAB] OR SARSCOV2[TIAB] OR "2019-nCoV"[TIAB] OR "Coronavirus Disease-19"[TIAB] OR "2019 Novel Coronavirus Disease"[TIAB] OR "SARS Coronavirus 2 Infection"[TIAB] OR "SARS-CoV-2"[TIAB] OR "COVID-19 Pandemic"[TIAB]	215.155
	#6	#4 OR #5	237.317
Population_Asthma	#7	Asthma[MeSH] OR "Bronchial Diseases"[MeSH] OR "Respiratory Hypersensitivity"[MeSH] OR "Status Asthmaticus"[MeSH]	229.748
	#8	Asthm*[TIAB] OR "bronchial spasm"[TIAB] OR bronchoconstriction[TIAB] OR "bronchial hyperreactivity"[TIAB] OR "respiratory hypersensitivity"[TIAB]	175.858
	#9	#7 OR #8	282.432
Population_total	#10	#3 AND #6 AND #9	467
Outcomes_Tomographic findings	#11	radiology[MeSH] OR "Multidetector Computed Tomography"[MeSH] OR "Tomography, X-Ray Computed"[MeSH] OR Tomography[MeSH]	1.695.459
	#12	"Multidetector Computed Tomography"[TIAB] OR "Multisection Computed Tomography"[TIAB] OR "Multislice Computed Tomography"[TIAB] OR "Diagnostic Imaging"[TIAB] OR "Computed Tomography"[TIAB] OR CT[TIAB]	567.458
	#13	#11 OR #12	1.943.866
Total	#14	#10 AND #13	16

**Table 3. Scopus research strategy**

<b>SEARCH DATE:</b> <b>22/02/2022</b>		<b>SCOPUS</b>	
<i>Items</i>	<i>#</i>	<i>Search terms</i>	<i>Number of citations</i>
Population_children	#1	TITLE-ABS-KEY (infan* OR child* OR pediatri* OR paediatric* OR adolescen* OR preschoo*)	
Population_SARS-CoV2	#2	TITLE-ABS-KEY ("COVID-19" OR "COVID19" OR "SARSCOV2" OR "2019-nCoV" OR "Coronavirus Disease-19" OR "2019 Novel Coronavirus Disease" OR "SARS Coronavirus 2 Infection" OR "SARS-CoV-2" OR "COVID-19 Pandemic")	
Population_Asthma	#3	TITLE-ABS-KEY (asthm* OR "bronchial spasm" OR bronchoconstrictio* OR "bronchial hyperreactivity" OR "respiratory hypersensitivity" OR "Bronchial Diseases")	
Outcomes_Tomographic findings	#4	TITLE-ABS-KEY ("Computed Tomography" OR "Multidetector Computed Tomography" OR "Multisection Computed Tomography" OR "Multislice Computed Tomography" OR "Diagnostic Imaging" OR CT OR radiology)	
Total	#5	#1 AND #2 AND #3 AND #4	37

Data from full articles were independently extracted into a database (Excel), which included the following elements: journal, year of publication, study design, population demographics (sex, age, comorbidities), size of the sample, tomographic findings of the thorax (patterns and location of disease involvement). Missing or unreported data were recorded as 'not reported'. GRADE system was employed for quality analysis of the articles [15].

**Table 4. Eligibility criteria**

This table reports the eligibility criteria for the selection of citations during the screening and full-text review.

ORDER	CATEGORY	EXCLUSION CRITERIA	NOTES
1	Duplicates, not in the language of interest.	Duplicates Not in the language of interest	
2	Nature of study	Not study type of interest	systematic reviews, meta-analyses, editorials and clinical guidelines
3	Population	No pediatric population No COVID-19 No asthma	
4	Outcomes	No tomographic findings	
5	Potential	Potential (no applicable exclusion criteria)	

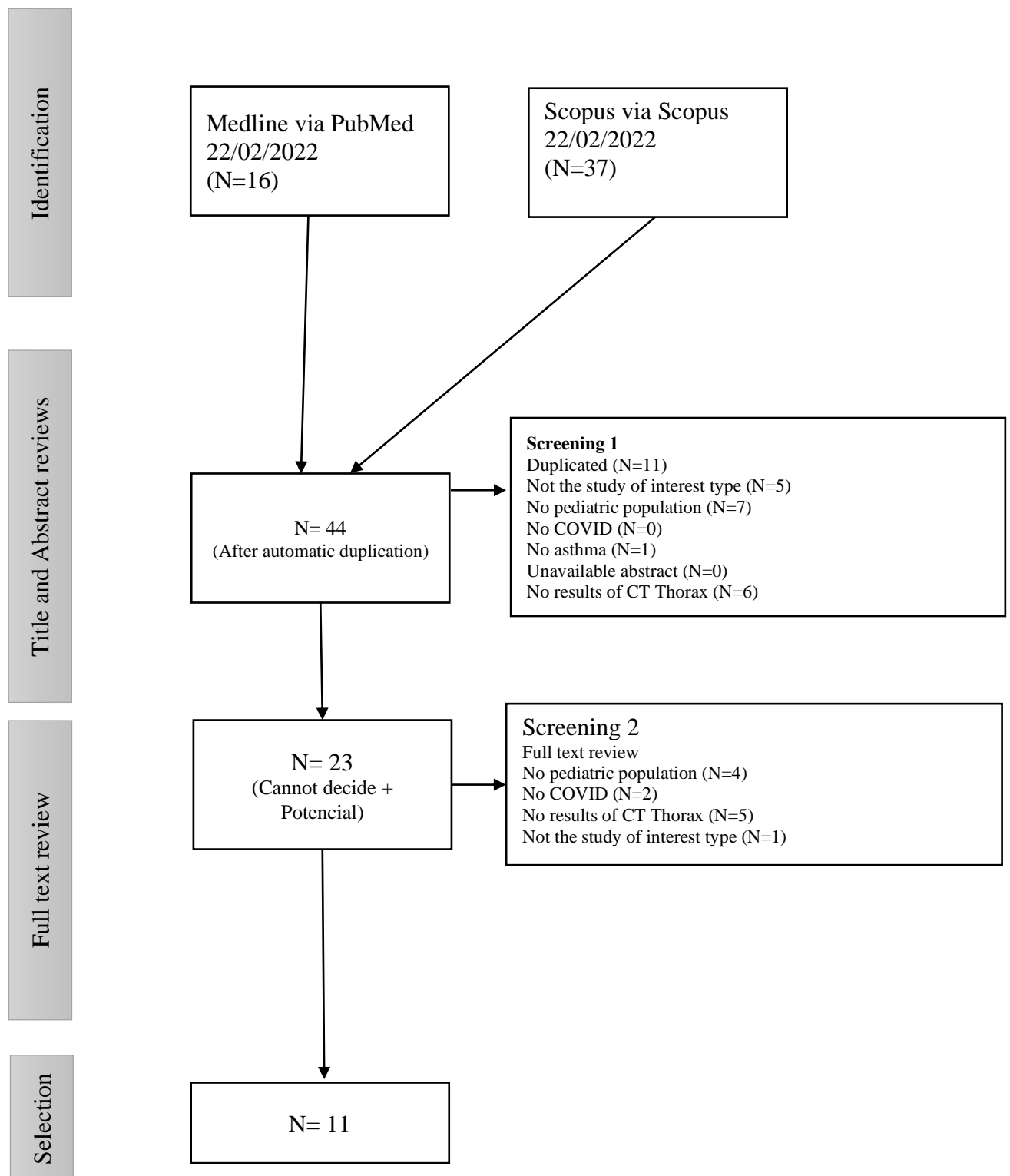
## RESULTS

The electronic bibliographic search was carried out on February 22, 2022 and initially yielded 53 articles; after automatic exclusion of duplicates, manual selection based on their title and abstract, and full text review resulted in 11 eligible articles ([Table 5](#)). Details are summarized in the PRISMA diagram ([Figure 1](#)). Sample sizes were small in most of the included studies, as pediatric cases of COVID-19 are rarely reported in the world. The studies selected for this review were observational and conducted between 2020 and 2021. These studies were conducted in Asia (n=5), North America (n=4), and Europe (n=2).

**Table 5. Citations list**

AUTHOR	TITLE	JOURNAL	PUBLICATION YEAR
Anastas et al.	Massive Pulmonary Embolism in an Adolescent With Multisystem Inflammatory Syndrome Due to COVID-19	Clinical Pediatrics	2021
Du et al	Clinical characteristics of 182 pediatric COVID-19 patients with different severities and allergic status	Allergy: European Journal of Allergy and Clinical Immunology	2021
Elghoudi et al	Covid-19 in Children and Young Adolescents in Al Ain, United Arab Emirates- a Retrospective Cross-Sectional Study	Front Pediatr	2020
Hashemi et al	Report of death in children with SARS-CoV-2 and human metapneumovirus (hMPV) coinfection: Is hMPV the trigger?	Journal of Medical Virology	2021
Karbuuz et al	Epidemiological, Clinical, and Laboratory Features of Children With COVID-19 in Turkey	Frontiers in Pediatrics	2021
Kotula et al	Bilateral pulmonary emboli in a teenager with positive SARS-CoV-2 antibody	Pediatric Pulmonology	2021
Li V. et al	Evaluating current chest imaging practices of pediatric patients with COVID-19: A retrospective analysis	Clinical Imaging	2021
Li Y. et al	Chest CT imaging characteristics of COVID-19 pneumonia in preschool children: A retrospective study	BMC Pediatrics	2020
Özdemir et al	COVID-19-Related Pneumonia in an Adolescent Patient with Allergic Asthma	Case Reports in Medicine	2021
Pina et al	COVID-19 in a pediatric cohort—retrospective review of chest computer tomography findings	Egyptian Journal of Radiology and Nuclear Medicine	2021
Romberg et al	Pediatric radiologic manifestations of COVID-19	Clinical Imaging	2021

Figure 2. PRISMA



Most of the pediatric population with and without asthma had normal chest tomographic patterns. Karbuz et al. mentions that the vast majority of the pediatric population, including asthmatic patients, presented a normal tomographic pattern, that is, no pathological findings were found in the tomography performed [2]. However, in a smaller number of children, both asthmatic and those without comorbidities presented abnormal tomography, of which the most frequent tomographic findings were: ground glass opacities, patch opacities, consolidations and peribronchial thickening [1,2,3,4,13,14,16] (Table 6).

In the pediatric population without comorbidities, the laterality of the tomographic findings of the thorax was presented in the same quantity. Li Y. et al. reported that there were equal numbers of reported cases with single lung field involvement (unilateral) and those with both lung field involvement (bilateral) in the pediatric population without comorbidities [4]. However, the same study reported that children with asthma had abnormal CT scans, with greater involvement of both lung fields (bilateral) [4] (Table 8).

In the pediatric population without comorbidities and in those with asthma, abnormal tomographic patterns occurred in greater numbers in a diffuse distribution, followed by a lower lobe distribution [4,6,7,16] (Table 9).

**Table 6. Tomographic thorax patterns of COVID-19 in children with and without asthma**

	CHILDREN WITHOUT ASTHMA							CHILDREN WITH ASTHMA						
	NORMAL PATTERN	GROUND GLASS OPACITY	PATCH OPACITY	CONSOLIDATED	PERIBRONCHIAL THICKENING	CRAZY PAVING	PULMONARY THROMBO EMBOLISM	NORMAL PATTERN	GROUND GLASS OPACITY	PATCH OPACITY	CONSOLIDATED	PERIBRONCHIAL THICKENING	CRAZY PAVING	PULMONARY THROMBO EMBOLISM
Anastas et al.	NR	NR	NR	NR	NR	NR	NR	NR	NR	NR	NR	NR	NR	1
Du et al	52	51	50	3	NR	NR	NR	NR	NR	NR	NR	NR	NR	NR
Elghoudi et al	NR	NR	NR	NR	NR	NR	NR	NR	NR	NR	NR	NR	NR	NR
Hashemi et al	NR	2	NR	NR	NR	NR	NR	NR	1	NR	NR	NR	NR	NR
Karbuz et al	275	126	NR	NR	NR	NR	NR	NR	NR	NR	NR	NR	NR	NR
Kotula et al	NR	NR	NR	NR	NR	NR	NA	NR	NR	NR	NR	NR	NR	1
Li V. et al	1	1	NR	1	NR	NR	NR	NR	NR	NR	NR	NR	NR	NR
Li Y. et al	1	1	1	2	1	NR	NR	NR	NR	2	NR	NR	NR	NR
Özdemir et al	NR	NR	NR	NR	NR	NR	NR	NR	1	NR	NR	NR	NR	NR
Pina et al	7	14	4	12	3	NR	NR	NR	NR	NR	NR	NR	NR	NR
Romberg et al	NR	4	NR	4	NR	2	NR	NR	NR	NR	NR	NR	NR	NR
<b>TOTAL</b>	<b>336</b>	<b>199</b>	<b>55</b>	<b>22</b>	<b>4</b>	<b>2</b>	<b>0</b>	<b>0</b>	<b>2</b>	<b>2</b>	<b>0</b>	<b>0</b>	<b>0</b>	<b>2</b>

**Table 8. Laterality of COVID-19 thorax tomographic findings in children with and without asthma.**

	CHILDREN WITHOUT ASTHMA		CHILDREN WITH ASTHMA	
	UNILATERAL	BILATERAL	UNILATERAL	BILATERAL
Anastas et al.	NR	NR	NR	1
Du et al	73	57	NR	NR
Elghoudi et al	8	6	NR	NR
Hashemi et al	NR	2	NR	1
Karbus et al	NR	NR	NR	NR
Kotula et al	NR	NA	NR	1
Li V. et al	NR	NR	NR	NR
Li Y. et al	3	3	NR	1
Özdemir et al	NR	NR	NR	1
Pina et al	2	15	NR	NR
Romberg et al	NR	4	NR	NR
TOTAL	86	87	0	5

**Table 9. Distribution of abnormal tomographic findings in the lung fields.**

	CHILDREN WITHOUT ASTHMA				CHILDREN WITH ASTHMA			
	DIFFUSE	UPPER LOBE	LOWER LOBE	DO NOT REPORT	DIFFUSE	UPPER LOBE	LOWER LOBE	DO NOT REPORT
Anastas et al.				X		X		
Du et al				X				X
Elghoudi et al				X				X
Hashemi et al	X				X			
Karbus et al				X				X
Kotula et al				X				X
Li V. et al			X					X
Li Y. et al	X						X	
Özdemir et al	X				X			
Pina et al	X							X
Romberg et al			X					X



In relation to the number of boys and girls without asthma and infected with COVID-19, no differences were found in the studies reported by Karbuz et al; Elghoudi et al; Li V. et al; Pina et al and Romberg et al, these studies showed that COVID-19 occurs in equal amounts in both boys and girls (Table 7). For children with asthma and COVID-19, there were no data reporting such a characteristic (Table 7).

Children with COVID-19 are often asymptomatic or have mild illness. Although they have chronic comorbidities such as asthma or allergic diseases, they may have a symptomatic condition but rarely a serious illness. The asthmatic pediatric population infected by COVID-19 presented in smaller numbers in relation to the rest of the pediatric population. In this sense, asthma does not increase susceptibility, morbidity and is not a predisposing factor for COVID-19 infection [1,6,7,10].

**Table 7. Distribution of pediatric population with and without asthma and affected by COVID-19.**

	CHILDREN WITHOUT ASTHMA		CHILDREN WITH ASTHMA	
	MEN	WOMEN	MEN	WOMEN
Anastas et al.	0	1	0	1
Du et al	120	62	1	0
Elghoudi et al	148	140	NR	NR
Hashemi et al	2	1	NR	NR
Karbuz et al	582	574	NR	NR
Kotula et al	0	1	0	1
Li V. et al	90	88	NR	NR
Li Y. et al	3	5	NR	NR
Özdemir et al	1	0	1	0
Pina et al	12	12	NR	NR
Romberg et al	11	13	NR	NR
TOTAL	969	897	2	2

## DISCUSSION AND CONCLUSION

This systematic review has included 11 articles reporting on the most frequent tomographic findings in asthmatic pediatric population infected with COVID-19. Although COVID-19 diagnosis relies on the clinical symptoms and contact history, laboratory tests and radiological studies are useful tools that not only help on the initial diagnosis but also in the follow-up of the disease and the effectiveness of the treatment [12]. In this review, we find that the largest number of CT scans performed did not show pathological results. However, abnormal CT scans characterized by the presence of diffusely distributed ground-glass opacities, patch opacities, consolidations and peribronchial thickening.

Thoracic computed tomography generates debate at the time of request. It should not be used frequently in children due to the lesser severity of the disease and the greater risk generated by the high radiation load. For these reasons, the radiation risk and the need for a scan must be pondered [3,12,13]. If pediatric patients have subjacent comorbidities, treatment failure, severe symptoms, or are critically ill, a tomographic study must be considered [3,7].

This review has described all the tomographic findings available to offer an overview of asthmatic pediatric population with COVID-19. There were limitations involved in this study due to articles lacking focus on asthmatic children or having reduced sample sizes [12]. In this sense, results could potentially be biased and generate shortcomings regarding the effects of COVID-19 in pediatric patients [12].

**BIBLIOGRAPHIC REFERENCES**

1. Anastas DC, Farias A, Runyon J, Laufer M, Sendi P, Totapally B, Sachdeva R. Massive Pulmonary Embolism in an Adolescent With Multisystem Inflammatory Syndrome Due to COVID-19. *Clin Pediatr (Phila)*. 2021 Jul;60(8):341-345. doi: 10.1177/00099228211015522. Epub 2021 May 12. PMID: 33980050.
2. Du H, Dong X, Zhang JJ, Cao YY, Akdis M, Huang PQ, Chen HW, Li Y, Liu GH, Akdis CA, Lu XX, Gao YD. Clinical characteristics of 182 pediatric COVID-19 patients with different severities and allergic status. *Allergy*. 2021 Feb;76(2):510-532. doi: 10.1111/all.14452. Epub 2020 Sep 3. PMID: 32524611; PMCID: PMC7307120.
3. Elghoudi A, Aldhanhani H, Ghatasheh G, Sharif E, Narchi H. Covid-19 in Children and Young Adolescents in Al Ain, United Arab Emirates- a Retrospective Cross-Sectional Study. *Front Pediatr*. 2021 Jan 18;8:603741. doi: 10.3389/fped.2020.603741. PMID: 33537264; PMCID: PMC7848192.
4. Hashemi SA, Safamanesh S, Ghasemzadeh-Moghaddam H, Ghafouri M, Mohajezadeh-Heydari MS, Namdar-Ahmadabad H, Azimian A. Report of death in children with SARS-CoV-2 and human metapneumovirus (hMPV) coinfection: Is hMPV the trigger? *J Med Virol*. 2021 Feb;93(2):579-581. doi: 10.1002/jmv.26401. Epub 2020 Aug 21. PMID: 32767680; PMCID: PMC7436913.

5. Karbuz A, Akkoc G, Bedir Demirdag T, Yilmaz Ciftdogan D, Ozer A, Cakir D, Hancerli Torun S, Kepenekli E, Erat T, Dalgic N, Ilbay S, Karaaslan A, Erdeniz EH, Aygun FD, Bozdemir SE, Hatipoglu N, Emiroglu M, Sahbudak Bal Z, Ciftci E, Bayhan GI, Gayretli Aydin ZG, Ocal Demir S, Kilic O, Hacimustafaoglu M, Sener Okur D, Sen S, Yahsi A, Akturk H, Cetin B, Sutcu M, Kara M, Uygun H, Tural Kara T, Korukluoglu G, Akgun O, Üstündağ G, Demir Mis M, Sali E, Kaba O, Yakut N, Kılıc O, Kanik MK, Cetin C, Dursun A, Cicek M, Kockuzu E, Sevketoglu E, Alkan G, Guner Ozenen G, İnce E, Baydar Z, Ozkaya AK, Ovali HF, Tekeli S, Celebi S, Cubukcu B, Bal A, Khalilova F, Kose M, Hatipoglu HU, Dalkiran T, Turgut M, Basak Altas A, Selcuk Duru HN, Aksay A, Saglam S, Sari Yanartas M, Ergenc Z, Akin Y, Duzenli Kar Y, Sahin S, Tuteröz SK, Bilen NM, Ozdemir H, Senoglu MC, Pariltan Kucukalioglu B, Besli GE, Kara Y, Turan C, Selbest Demirtas B, Celikyurt A, Cosgun Y, Elevli M, Sahin A, Bahtiyar Oguz S, Somer A, Karadag B, Demirhan R, Turk Dagi H, Kurugol Z, Taskin EC, Sahiner A, Yesil E, Ekemen Keles Y, Sarikaya R, Erdem Eralp E, Ozkinay F, Konca HK, Yilmaz S, Gokdemir Y, Arga G, Ozen S, Coksuer F, Vatansever G, Tezer H, Kara A. Epidemiological, Clinical, and Laboratory Features of Children With COVID-19 in Turkey. *Front Pediatr.* 2021 May 7;9:631547. doi: 10.3389/fped.2021.631547. PMID: 34055680; PMCID: PMC8161543.
6. Kotula JJ, Balakumar N, Khan D, Patel B. Bilateral pulmonary emboli in a teenager with positive SARS-CoV-2 antibody. *Pediatr Pulmonol.* 2021 Jan;56(1):271-273. doi: 10.1002/ppul.25132. Epub 2020 Nov 5. PMID: 33095516.

7. Li VR, Sura A, Pickering T. Evaluating current chest imaging practices of pediatric patients with COVID-19: A retrospective analysis. *Clin Imaging*. 2021 Dec;80:300-303. doi: 10.1016/j.clinimag.2021.08.019. Epub 2021 Aug 27. PMID: 34479095; PMCID: PMC8393515.
8. Li Y, Cao J, Zhang X, Liu G, Wu X, Wu B. Chest CT imaging characteristics of COVID-19 pneumonia in preschool children: a retrospective study. *BMC Pediatr*. 2020 May 18;20(1):227. doi: 10.1186/s12887-020-02140-7. PMID: 32423435; PMCID: PMC7232932.
9. Özdemir Ö, Nezir Engin MM, Yılmaz EA. COVID-19-Related Pneumonia in an Adolescent Patient with Allergic Asthma. *Case Rep Med*. 2021 Oct 7;2021:6706218. doi: 10.1155/2021/6706218. PMID: 34642587; PMCID: PMC8502245.
10. Pina Prata R, Forjaco A, Ruano CA, Lopes Dias J, Fernandes L, Ferreira A, Alves P, Cabrita Carneiro R, Nunes A, Soares E. COVID-19 in a pediatric cohort—retrospective review of chest computer tomography findings. *Egypt J Radiol Nucl Med*. 2021;52(1):83. doi: 10.1186/s43055-021-00461-w. Epub 2021 Mar 24. PMCID: PMC7989716.
11. Romberg EK, Menashe SJ, Kronman MP, Tang ER, Stanescu AL, Otto RK, Otjen JP. Pediatric radiologic manifestations of COVID-19. *Clin Imaging*. 2021 Jul;75:165-170. doi: 10.1016/j.clinimag.2021.03.032. Epub 2021 Mar 30. PMID: 33831747; PMCID: PMC8008832.

12. Liguoro I, Pilotto C, Bonanni M, Ferrari ME, Pusiol A, Nocerino A, Vidal E, Cogo P. SARS-COV-2 infection in children and newborns: a systematic review. *Eur J Pediatr.* 2020 Jul;179(7):1029-1046. doi: 10.1007/s00431-020-03684-7. Epub 2020 May 18. Erratum in: *Eur J Pediatr.* 2021 Jul;180(7):2343. PMID: 32424745; PMCID: PMC7234446.
13. Chang TH, Wu JL, Chang LY. Clinical characteristics and diagnostic challenges of pediatric COVID-19: A systematic review and meta-analysis. *J Formos Med Assoc.* 2020 May;119(5):982-989. doi: 10.1016/j.jfma.2020.04.007. Epub 2020 Apr 16. PMID: 32307322; PMCID: PMC7161491.
14. Nino G, Zember J, Sanchez-Jacob R, Gutierrez MJ, Sharma K, Linguraru MG. Pediatric lung imaging features of COVID-19: A systematic review and meta-analysis. *Pediatr Pulmonol.* 2021 Jan;56(1):252-263. doi: 10.1002/ppul.25070. Epub 2020 Nov 2. PMID: 32926572; PMCID: PMC8287438.
15. Katal S, Johnston SK, Johnston JH, Gholamrezanezhad A. Imaging Findings of SARS-CoV-2 Infection in Pediatrics: A Systematic Review of Coronavirus Disease 2019 (COVID-19) in 850 Patients. *Acad Radiol.* 2020 Nov;27(11):1608-1621. doi: 10.1016/j.acra.2020.07.031. Epub 2020 Jul 30. PMID: 32773328; PMCID: PMC7392075.
16. Shelmerdine SC, Lovrenski J, Caro-Domínguez P, Toso S; Collaborators of the European Society of Paediatric Radiology Cardiothoracic Imaging Taskforce.

Coronavirus disease 2019 (COVID-19) in children: a systematic review of imaging findings. *Pediatr Radiol.* 2020 Aug;50(9):1217-1230. doi: 10.1007/s00247-020-04726-w. Epub 2020 Jun 18. PMID: 32556807; PMCID: PMC7300372.